

OPEN ACCESS



# African Journal of Biochemistry Research

May 2019  
ISSN 1996-0778  
DOI: 10.5897/AJBR  
[www.academicjournals.org](http://www.academicjournals.org)



**ACADEMIC  
JOURNALS**  
expand your knowledge

# About AJBR

African Journal of Biochemistry Research (AJBR) provides rapid publication (monthly) of articles in all areas of Biochemistry such as Nutritional biochemistry, Analytical biochemistry, Clinical Biochemistry, Human and Plant Genetics, Molecular and Cell Biology, Enzymology, Toxicology, Plant Biochemistry, Biochemistry Education etc. The Journal welcomes the submission of manuscripts that meet the general criteria of significance and scientific excellence. Papers will be published shortly after acceptance. All articles are peer-reviewed.

## Indexing

[CAB Abstracts](#), [CABI's Global Health Database](#), [Chemical Abstracts \(CAS Source Index\)](#), [Dimensions Database](#), [Google Scholar](#), [Matrix of Information for The Analysis of Journals \(MIAR\)](#), [Microsoft Academic](#)

## Open Access Policy

Open Access is a publication model that enables the dissemination of research articles to the global community without restriction through the internet. All articles published under open access can be accessed by anyone with internet connection.

The African Journal of Biochemistry Research is an Open Access journal. Abstracts and full texts of all articles published in this journal are freely accessible to everyone immediately after publication without any form of restriction.

## Article License

All articles published by African Journal of Biochemistry Research are licensed under the [Creative Commons Attribution 4.0 International License](#). This permits anyone to copy, redistribute, remix, transmit and adapt the work provided the original work and source is appropriately cited. Citation should include the article DOI. The article license is displayed on the abstract page the following statement:

This article is published under the terms of the [Creative Commons Attribution License 4.0](#)  
Please refer to <https://creativecommons.org/licenses/by/4.0/legalcode> for details about [Creative Commons Attribution License 4.0](#)

## **Article Copyright**

When an article is published by in the African Journal of Biochemistry Research, the author(s) of the article retain the copyright of article. Author(s) may republish the article as part of a book or other materials. When reusing a published article, author(s) should; Cite the original source of the publication when reusing the article. i.e. cite that the article was originally published in the African Journal of Biochemistry Research. Include the article DOI Accept that the article remains published by the African Journal of Biochemistry Research (except in occasion of a retraction of the article)

The article is licensed under the Creative Commons Attribution 4.0 International License.

A copyright statement is stated in the abstract page of each article. The following statement is an example of a copyright statement on an abstract page.

Copyright ©2016 Author(s) retains the copyright of this article.

## **Self-Archiving Policy**

The African Journal of Biochemistry Research is a RoMEO green journal. This permits authors to archive any version of their article they find most suitable, including the published version on their institutional repository and any other suitable website.

Please see <http://www.sherpa.ac.uk/romeo/search.php?issn=1684-5315>

## **Digital Archiving Policy**

The African Journal of Biochemistry Research is committed to the long-term preservation of its content. All articles published by the journal are preserved by [Portico](#). In addition, the journal encourages authors to archive the published version of their articles on their institutional repositories and as well as other appropriate websites.

<https://www.portico.org/publishers/ajournals/>

## **Metadata Harvesting**

The African Journal of Biochemistry Research encourages metadata harvesting of all its content. The journal fully supports and implement the OAI version 2.0, which comes in a standard XML format. [See Harvesting Parameter](#)

# Memberships and Standards



Academic Journals strongly supports the Open Access initiative. Abstracts and full texts of all articles published by Academic Journals are freely accessible to everyone immediately after publication.



All articles published by Academic Journals are licensed under the [Creative Commons Attribution 4.0 International License \(CC BY 4.0\)](#). This permits anyone to copy, redistribute, remix, transmit and adapt the work provided the original work and source is appropriately cited.



[Crossref](#) is an association of scholarly publishers that developed Digital Object Identification (DOI) system for the unique identification published materials. Academic Journals is a member of Crossref and uses the DOI system. All articles published by Academic Journals are issued DOI.

[Similarity Check](#) powered by iThenticate is an initiative started by CrossRef to help its members actively engage in efforts to prevent scholarly and professional plagiarism. Academic Journals is a member of Similarity Check.

[CrossRef Cited-by Linking](#) (formerly Forward Linking) is a service that allows you to discover how your publications are being cited and to incorporate that information into your online publication platform. Academic Journals is a member of [CrossRef Cited-by](#).



Academic Journals is a member of the [International Digital Publishing Forum \(IDPF\)](#). The IDPF is the global trade and standards organization dedicated to the development and promotion of electronic publishing and content consumption.

## Contact

Editorial Office: [ajbr@academicjournals.org](mailto:ajbr@academicjournals.org)

Help Desk: [helpdesk@academicjournals.org](mailto:helpdesk@academicjournals.org)

Website: <http://www.academicjournals.org/journal/AJBR>

Submit manuscript online <http://ms.academicjournals.org>

Academic Journals  
73023 Victoria Island, Lagos, Nigeria  
ICEA Building, 17th Floor,  
Kenyatta Avenue, Nairobi, Kenya.

**Prof. Johnson Lin**

School of Biochemistry, Genetics, Microbiology and Plant Pathology  
University of KwaZulu-Natal (Westville)  
Private Bag X 54001, Durban  
Republic of South Africa

**Editorial Board Members**

**Dr. Ahmed Malki**

Biochemistry Department  
Faculty of Science  
Alexandria University  
Alexandria,  
Egypt.

**Dr. Rouabhi Rachid**

Biology Department  
Tebessa University  
Algeria.

**Prof. Christine Clayton**

Zentrum für Molekulare Biologie der Universität Heidelberg (ZMBH)  
Heidelberg  
Germany.

**Ass. Prof. Alfonso Baldi**

Dept. Biochemistry, Sect. Pathology  
Second University of Naples,  
Italy.

**Dr. Oluwole Ariyo**

Allen University  
USA.

**Prof. Belkhodja Moulay**

University of Senia Oran  
Algeria.

**Prof. Emmanuel Anosike**

Department of Biochemistry  
University of Port Harcourt  
Nigeria.

**Ahmed Ragab Gaber**

Division of Anatomy and Embryology, Zoology department,  
Faculty of Science, Beni-Suef University,  
Egypt.

## **Table of Content**

### **Immunomodulatory effects of cement in exposed workers**

Moses O. Akiibinu, Taofeeq Oduola and Franklin Akinola

### **Phytochemical, acute and subacute toxicity studies of *Annona senegalensis* Pers. (Annonaceae) root wood extracts**

Sylvain ILBOUDO, Hortense SOME, Geoffroy G. OUEDRAOGO,  
Félix B. KINI, Sylvain OUEDRAOGO and Innocent P. GUISSOU

*Full Length Research Paper*

## **Immunomodulatory effects of cement in exposed workers**

**Moses O. Akiibinu<sup>1\*</sup>, Taofeeq Oduola<sup>2</sup> and Franklin Akinola<sup>3</sup>**

<sup>1</sup>Department of Chemistry and Biochemistry, Caleb University, Lagos, Nigeria.

<sup>2</sup>Department of Chemical Pathology, Faculty of Medical Laboratory Sciences, Usmanu Danfodiyo University, Sokoto, Nigeria.

<sup>3</sup>Department of Medical Laboratory Sciences, Ladoke Akintola University, Ogbomoso, Osun State, Nigeria.

Received 24 December, 2018; Accepted 20 March, 2019

**This study was conducted to assess the immunomodulatory potentials [immunoglobulin E (IgE), interferon-gamma (IFN- $\gamma$ ) and tumor necrosis factor-alpha (TNF- $\alpha$ )] of cement dust in individuals occupationally exposed to cement. Potentials of cement particles to modulate immune responses have not been documented in occupationally exposed Nigerians. Twenty-nine male cement loaders who had direct exposure to cement dust and gases for a period of 2 to 30 years in Elephant/Lafarge Cement Depot Ibadan, Nigeria, were recruited for this study. Another twenty apparently healthy individuals who had no interaction with cement served as controls. Plasma levels of IgE, IFN- $\gamma$  and TNF- $\alpha$  were determined in them using enzyme linked immunosorbent assay (ELISA) methods. The results showed significantly ( $p < 0.05$ ) higher level of plasma IgE in cement loaders compared with controls. IFN- $\gamma$  decreased significantly ( $p < 0.05$ ) in cement loaders, while TNF- $\alpha$  did not show significant ( $p > 0.05$ ) change in the cement loaders compared with controls. There was no significant ( $p > 0.05$ ) correlation between the IgE, IFN- $\gamma$ , TNF- $\alpha$  and period of exposure in the cement loaders. Cement dust could evoke IgE production and possibly inhibit certain cell types secreting IFN- $\gamma$  in occupationally exposed workers. Clinicians and researchers may need to rule out recent exposure to cement dust when working on type I hypersensitivity conditions.**

**Key words:** Cement, allergen, Interferon- $\gamma$ , necrotic factor-alpha.

### **INTRODUCTION**

Cement dust basically contains calcium oxide, silicon oxide, aluminium oxide, iron oxide, potassium, sodium, sulphur, magnesium oxide, cobalt and heavy metals like chromium, chromium, nickel, lead and mercury (Fell et al., 2003; Gbadebo and Bankole, 2007). The cement dust

has a diameter ranging from 0.05 to 5.0  $\mu$  (Abrons et al., 1997) emitted in form of particulate matters or aerosol that can be ingested or inhaled by exposed individuals (Green, 1970). Heather (2003) reported that exposure to cement dust for a short period may not cause serious

\*Corresponding author. E-mail: akiibinumoses@yahoo.com.



problems. However, prolonged exposure can cause severe irreversible damage to plants and animals. Pathological effects of cement dusts have been reported in some visceral organs including lungs, kidney and liver (ATSDR, 2000; Abrons et al., 1988). Other studies have reported increased free radical generation and inflammatory responses in workers exposed to cement dust. Ikli et al. (2003) stressed that in organs like kidneys, skin and liver, cellular activation in response to the cement particulate matters leads to inflammatory responses and excessive production of reactive oxygen species. Akiibinu et al. (2016) reported that excessive macrophage activation, oxidative DNA damage, kidney diseases and chemically-induced tumors are imminent in cement exposed workers. Koh et al. (2013) observed increased cancer incidence in the cement exposed workers.

There are studies linking exposure to cement dust with changes in lung functions and inflammation of the peripheral lung (Mengesha and Bekele, 1997; Mwaiselage et al., 2005; Sauni et al., 2012). Several reports on respiratory diseases in long-term cement-dust exposed workers revealed irritation of the exposed mucous membranes (Schwartz, 1994; Sivicommar et al., 2001; Zeleke et al., 2010). Other studies show that inhaled cement particles cause activation of alveolar macrophages, mesothelial cells and lung fibroblasts that may contribute to higher plasma levels of free radicals and some products of cellular activation in the cement exposed workers (Aminian et al., 2008; Zeleke et al., 2010). There is increasing evidence that respiratory sensitization by allergens is associated with the preferential activation of Th-2 cells and their products, for example, interleukin (IL)-4, IL-5, IL-10, and IL-13; that favor type 1-hypersensitivity reactions and promote IgE antibody production (Dearman et al., 2003). Certain constituents of cement products including acrylates, nickel, cobalt, chromium and polymerization additives in bone cement (for example., benzoyl peroxide) have been implicated as triggers of eczema, wound healing disorders, and aseptic implant loosening (Fröschen et al., 2018; Chen et al., 2018).

Most of the previous studies have evaluated the effects of cement dust exposure on lung disorders by using spirometry or radiology. No one has attempted to study the antigenic potentials of cement particles and status of cellular activities in cement loaders. This study was therefore designed to bridge this gap in knowledge by determining the plasma levels of IgE, IFN- $\gamma$  and TNF- $\alpha$  in Nigerian cement loaders.

## MATERIALS AND METHODS

### Sample collection

Twenty-nine cement loaders working in the Elephant/Larfage Cement Depot volunteered to participate in this study. These workers were untrained and lacked appropriate protective equipment that could prevent dermal, oral and lung contact with

cement particles. Another twenty apparently healthy individuals who had no interaction with cement served as controls. All participants were screened and found free from worm infections at the time of this study. The body weight and height of participants were taken, and the body mass index (BMI) calculated. Five milliliter of fasting blood sample was collected from each participant into lithium heparin bottle, centrifuged and the plasma stored at -20°C until ready for analysis. This study was approved by the Institutional Review Board (ref. no: CULREC 02/007), and informed consent obtained from all participants before the commencement of this study.

### Determination of IgE, TNF- $\alpha$ and IFN- $\gamma$

Plasma level of IgE was determined using commercially prepared ELISA kits (cat. numbers T1244A) by Calbiotech Inc., 1935 Cordell Ct., El Cajon, CA 92020. Plasma levels of TNF- $\alpha$  and IFN- $\gamma$  were determined using commercially prepared ELISA kits (cat. numbers EKHU-0162 and EKHU-0110 respectively) by Melsin Medical Co. Limited, Jilin Province, China. The methods employed for the determination of IgE, TNF- $\alpha$  and IFN- $\gamma$  was provided by the manufacturers of the ELISA kits.

### Statistical analysis

All statistical analyses were performed using Statistical Package for Social Sciences (SPSS), version 21.0. The data were expressed as Mean $\pm$ SD. Student T-test was used for comparison of analytes in cement loaders and controls. Pearson correlation coefficient ( $r$ ) was calculated and  $P$  values less than 0.05 were considered significant.

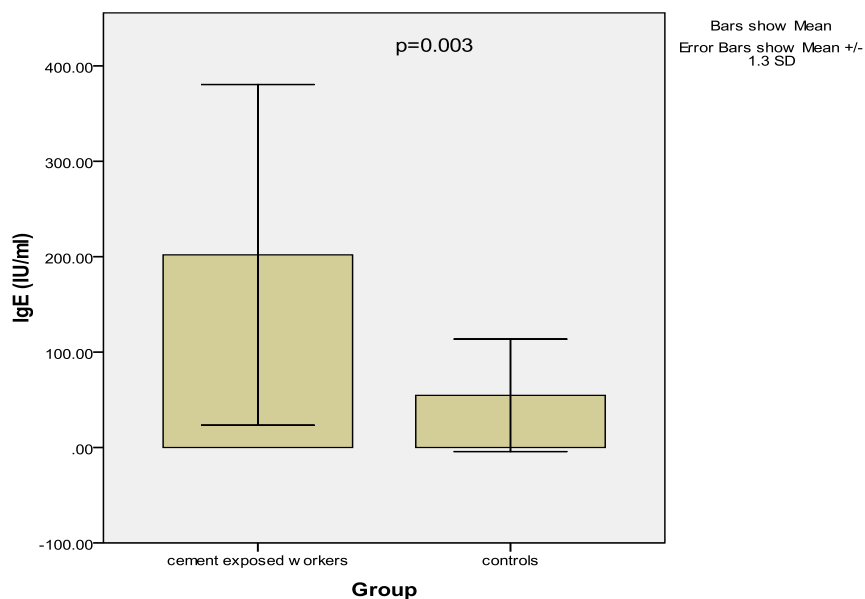
## RESULTS AND DISCUSSION

There were no significant ( $p>0.05$ ) differences in the values of age, weight, height and BMI of the cement loaders and controls recruited for this study (Table 1). Plasma IgE increased significantly ( $201.9\pm 137.3$  iu/ml versus  $54.7\pm 45.3$  iu/ml;  $p=0.003$ ) in cement loaders compared with controls (Figure 1). IFN- $\gamma$  decreased significantly ( $65.4\pm 14.9$  pg/ml versus  $151.6\pm 78.4$  pg/ml;  $p<0.001$ ) in cement loaders compared with controls (Figure 2). Level of TNF- $\alpha$  did not show significant ( $84.4\pm 50.8$  pg/ml versus  $109.9\pm 72.0$  pg/ml;  $p=0.24$ ) difference in the cement loaders compared with controls (Figure 3). There was no significant ( $p>0.05$ ) correlation between the IgE, IFN- $\gamma$ , TNF- $\alpha$  and period of exposure in the cement loaders (Table 2).

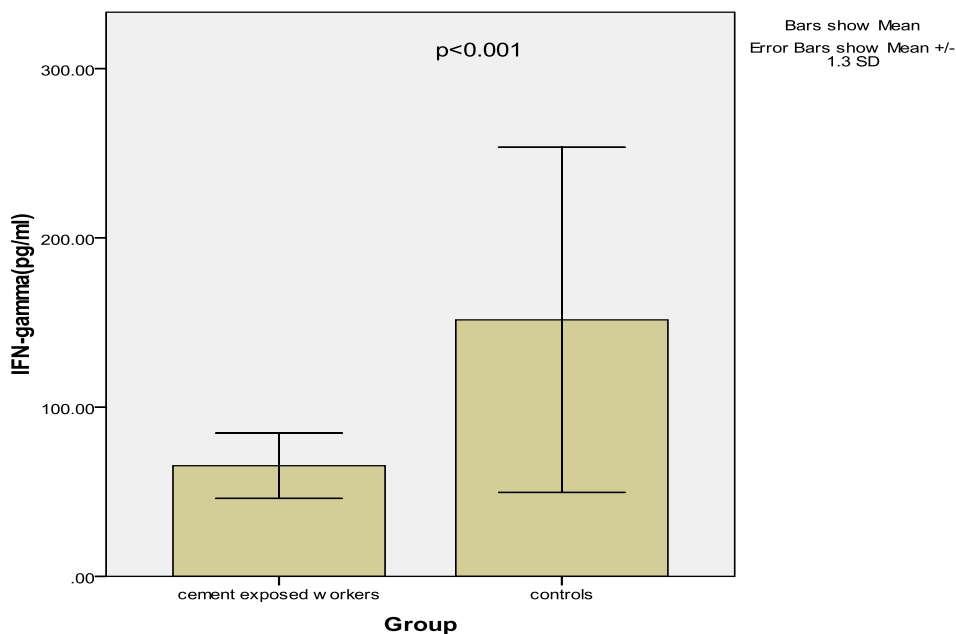
Workers in cement industries are exposed to different levels of dust. A geometric mean dust exposure of  $38.6$  mg/m<sup>3</sup> was reported in the crusher section followed by  $18.5$  mg/m<sup>3</sup> in the packing section, while the guards are exposed to only  $0.4$  mg/m<sup>3</sup> (Mengesha and Bekele, 1997; Mwaiselage et al., 2005; Zeleke et al., 2010). Koike et al. (2008) and Fell et al. (2010) stressed that particulate matters can enhance antigen-related airway inflammation and immunoglobulin production. The cement packers (loaders) recruited for this study lacked protective gargets and are therefore prone to both dermal and lung exposure more than other workers in cement industry. Significantly higher level of plasma IgE observed in these

**Table 1.** Physical characteristics of cement loaders and controls.

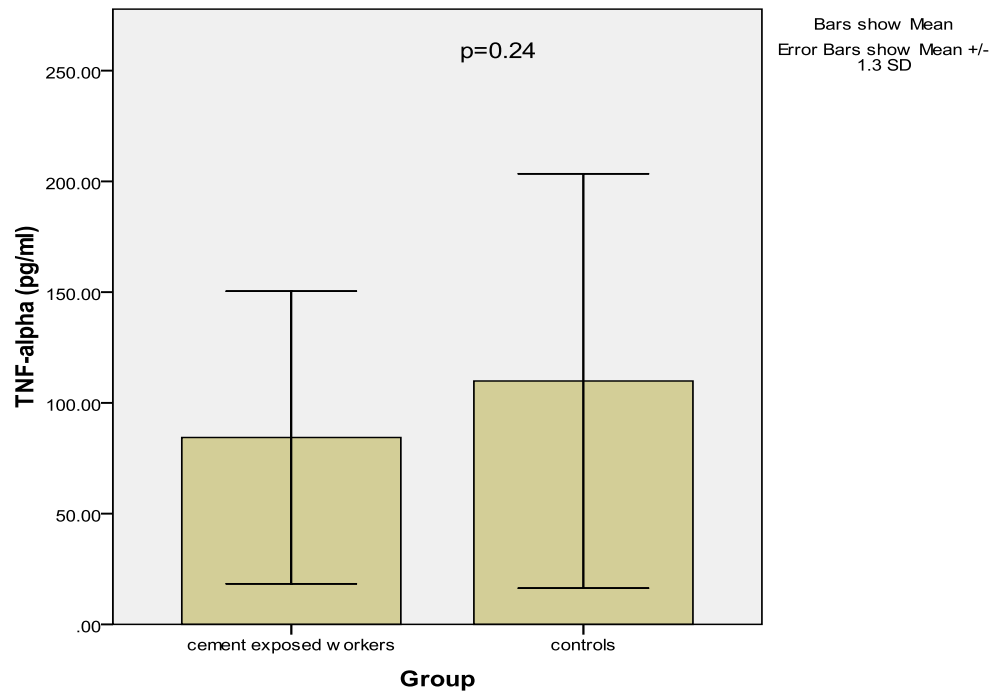
Parameter	Controls (N=20)	Cement Loaders (N=29)	p-value
Age (years)	46.17±15.03	51.76±8.81	0.217
Weight (kg)	69.56±9.84	66.62±11.93	0.376
Height (m)	1.68±0.07	1.69±0.07	0.703
BMI (kg/m <sup>2</sup> )	24.64±3.54	22.89±3.38	0.187



**Figure 1.** Levels of plasma IgE in cement loaders and controls.



**Figure 2.** Levels of plasma IFN- $\gamma$  in cement loaders and controls.



**Figure 3.** Levels of plasma TNF-alpha in cement loaders and controls.

**Table 2.** Correlation between the levels of IgE, TNF- $\alpha$  and IFN- $\gamma$  and period of exposure (p/exp) in cement loaders (N=29)

Parameter	r-value	p-value
IgE/p/exp	-0.046	0.815
IgE/TNF- $\alpha$	0.186	0.335
IgE/IFN- $\gamma$	-0.060	0.757

cement loaders could be due to allergic reactions induced by the cement particles. This study agrees with Ogunbileje and Akinosun (2011) who reported significantly higher level of IgE in some cement factory workers. Shankar et al. (2017) stressed that postcementation hypersensitivity is an unpleasant sensation experienced by their patients. Rahmani et al. (2018) reported allergy and other complication like hypertension, diabetes and backache in workers exposed to cement dust. Other previous studies show that dermal exposure to chromium content of cement causes skin irritation and activate keratinocytes in allergic contact dermatitis (Kanerva et al., 2000; Gueniche et al., 1994; Estlander et al., 2000; Kvitko, 2001; Thomas et al., 2000; Lejding et al., 2018). The chromium induces two types of hypersensitivity reactions: type I, anaphylactic type, and type IV, the delayed-type hypersensitivity (Thomas et al., 2000). Mowitz et al. (2016) reported that potassium dichromate and ethylenediamine dihydrochloride and/or amines used as additives in cement also induce contact

allergy in the cement exposed workers. Dearman et al. (2003) reported that allergic sensitization induced by chromate is associated with preferential activation of Th-2 cells and their products that favor immediate type hypersensitivity reactions, promoting IgE antibody production and clinical manifestations of allergic responses. Sarma (2009) also reported frequent allergic reaction among construction workers using cement. Other reports show that exposure to cement enhances IgG, IgA (Nigam et al., 1994; Aminian et al., 2008) and IgM production (Karnik et al., 1991). This chromate sensitization was found reduced with the usage of chromate-reduced cement (Geier et al., 2017). Possible inhibitory effects of some heavy metal constituents of cement (for example, nickel, chromium, lead and mercury) on tissue macrophages and natural killer cells might account for the lower level of IFN- $\gamma$  observed in this study. This finding seems to agree with Castranova (2004) who reported inhibitory effects of heavy metals on oxidative metabolic processes in alveolar macrophages.

However, our report contradicts that of Carlsten et al. (2007) who reported significantly higher serum IFN- $\gamma$  in cement-dust exposed apprentices. There was no significant change in the level of TNF- $\alpha$  induced by cement in the exposed workers. This could be due to the effects of some inhibitory factors antagonizing the activation of macrophages. In a research by Algan et al. (1996), it was stated that exposure of macrophages to polymethylmethacrylate (a component of cement) particles leads to a significant release of TNF- $\alpha$  after a long time of contact.

Conclusively, cement dust could evoke IgE production and possibly inhibit certain cell types secreting IFN- $\gamma$  in occupationally exposed workers. Clinicians and researchers may need to rule out recent exposure to cement dust when working on type I hypersensitivity conditions.

## CONFLICT OF INTERESTS

The authors have not declared any conflicts of interests.

## REFERENCES

- Abrons HL, Petersen MR, Sanderson WT, Engelberg AL, Harber P (1988). Symptoms, ventilatory function, and environmental exposures in Portland cement workers. *British Journal of Industrial Medicine* 45:368-75.
- Abrons HL, Petersen MR, Sanderson WT, Engelberg AL, Harber P (1997). Chest radiography in Portland cement workers. *Journal of Occupational and Environmental Medicine* 39:1047-1054.
- Agency for Toxic Substances and Disease Registry (ATSDR) (2000). Toxicological Profile for Chromium. Atlanta, GA: U.S. Department of Health and Human Services, Public Health Service.
- Akiibinu M, Adeyemi M, Ogunbiyi T, Amusah M, Amusan A, Anetor J (2016). Metabolic disorders in Nigerians occupationally exposed to cement dust. *European Scientific Journal* 12(33):57.
- Algan SM, Purdon M, Horowitz SM (1996). Role of tumor necrosis factor alpha in particulate-induced bone resorption. *Journal of Orthopaedic Research* 14(1):30-35.
- Aminian O, Sharifian SA, Mehrdad R, Kaht Narooy H, Giahi O (2008). Humoral immune system alterations in silica exposed workers. *Iranian Journal of Public Health* 37(3):142-145.
- Carlsten C, de Roos AJ, Kaufman JD, Checkoway H, Wener M, Seixas N (2007). Cell markers, cytokines, and immune parameters in cement mason apprentices. *Arthritis Care and Research: Official Journal of the American College of Rheumatology* 57(1):147-153.
- Castranova V (2004). Signaling pathways controlling the production of inflammatory mediators in response to crystalline silica exposure: role of reactive oxygen/nitrogen species. *Free Radical Biology and Medicine* 37:916-925.
- Chen CT, Ng KJ, Lin Y, Kao MC (2018). Red man syndrome following the use of vancomycin-loaded bone cement in the primary total knee replacement: A case report. *Medicine (Baltimore)* 97(51):e13371.
- Dearman RJ, Betts CJ, Humphreys N, Flanagan BF, Gilmour NJ, Basketter DA, Kimber I (2003). Chemical allergy: considerations for the practical application of cytokine profiling. *Toxicological Sciences* 71(2):137-45. PMID:12563099
- Estlander T, Jolanki R, Kanerva L (2000). Occupational allergic contact dermatitis from trivalent chromium in leather tanning. *Contact Dermatitis* 43:114-116.
- Fell AK, Thomassen TR, Kristensen P, Egeland T, Kongland J (2003). Respiratory symptoms and ventilatory function in workers exposed to portland cement dust. *Journal of Occupational and Environmental Medicine* 45:1008-1014.
- Fell AK, Sikkeland LI, Svendsen MV, Kongerud J (2010). Airway inflammation in cement production workers. *Occupational and Environmental Medicine* 67(6):395-400.
- Fröschen FS, Gravius N, Lau JF, Randau TM, Kaup E, Friedrich MJ, Gravius S (2018). A case series of cementless revision total knee arthroplasty in patients with benzoyl peroxide allergy. *International Orthopaedics* 11:1-9.
- Gbadebo AM, Bankole OD (2007). Analysis of Potentially Toxic Metals in Airborne Cement Dust around Sagamu, Southwest, Nigeria. *Journal of Applied Science* 7: 35-40.
- Geier J, Lessmann H, Skudlik C, Ballmer-Weber BK, Weisshaar E, Uter W, Schnuch A (2017). Occupational contact allergy in bricklayers, tile setters etc. - Current spectrum of sensitization and recent time trends. *Allergologie Select* 1(2):127-140.
- Green GM (1970). The J. Burns Amberson lecture. In defense of lung. *American Review of Respiratory Disease* 102:691-703.
- Gueniche A, Viae J, Lizard G, Charveron M, Schmitt D (1994). Effect of various metals on intercellular adhesion molecule-1 expression and tumor necrosis factor alpha production by normal human Keratinocytes. *Archives of Dermatological Research* 286(8):466-470.
- Heather G (2003). Effects of Air Pollution on Agricultural Crops. Ministry of Agricultural, Air Pollution on Agricultural Crops, Ontario, Canada. Order No. 85-002.
- Ikli BI, Demir TA, Urer SM, Bekler A, Akar T, Kalyoncu C (2003). Effects of chromium exposure from a cement factory. *Environmental Research* 9:113-118.
- Karnik AB, Saiyed HN, Nigam SK (1991). Humoral immunologic dysfunction in silicosis. *The Indian Journal of Medical Research* 92:440-442
- Kanerva L, Jolanki R, Estlander T, Alanko K, Savela A (2000). Incidence rates of occupational allergic contact dermatitis caused by metals. *American Journal of Contact Dermatitis* 11:155-160.
- Koh DH, Kim TW, Jang S, Ryu HW (2013). Dust exposure and the risk of cancer in cement industry workers in Korea. *American Journal of Industrial Medicine* 56(3) 276-281.
- Koike E, Takano H, Inoue KI, Yanagisawa R, Sakurai M, Aoyagi H, Shinohara R, Kobayashi T (2008). Pulmonary exposure to carbon black nanoparticles increases the number of antigen-presenting cells in murine lung. *International Journal of Immunopathology and Pharmacology* 21(1):35-42.
- Kvitko E (2001). Occupational contact dermatitis in the tanning industry. *Contact Dermatitis* 45:256-259.
- Lejding T, Mowitz M, Isaksson M, Bruze M, Pontén A, Svedman C, Zimerson E, Engfeldt M (2018). A retrospective investigation of hexavalent chromium allergy in southern Sweden. *Contact Dermatitis* 78(6):386-392.
- Mengesha YA, Bekele A (1997). Effects of acute exposure to different occupational dusts on pulmonary function indices of factory workers in Ethiopia. *African Newsletter on Occupational Health and Safety* 7:8-9.
- Mowitz M, Zimerson E, Hauksson I, Pontén A (2016). Chromate and amine contact allergies in workers manufacturing precast concrete elements. *Contact Dermatitis* 75(6):363-369.
- Mwaiselage J, Moen B, Bråtvæit M (2005). Acute respiratory health effects among cement factory workers in Tanzania: an evaluation of a simple health surveillance tools. *International Archives of Occupational and Environmental Health* 79:49-56.
- Nigam SK, Suthar AM, Patel MM, Karnik AB, Dave SK, Kashyap SK, Venkaiah K (1994). Humoral immunological profile of workers exposed to asbestos in asbestos mines. *The Indian Journal of Medical Research* 98:274-277.
- Ogunbileje JO, Akinosun OM (2011). Biochemical and haematological profile in Nigerian cement factory workers. *Research Journal of Environmental Toxicology* 5:133-140.
- Rahmani AH, Almatroudi A, Babiker AY, Khan AA, Alsahly MA (2018). Effect of exposure to cement dust among the workers: An evaluation of health related complications. Open access Macedonian Journal of Medical Sciences 6(6):1159-1162.
- Sarma N (2009). Occupational allergic contact dermatitis among construction workers in India. *Indian Journal of Dermatology* 54(2):137-41.
- Sauni R, Oksa P, Lehtimäki L, Toivio P, Palmroos P, Nieminen R,

- Moilanen E, Uitti J (2012). Increased alveolar nitric oxide and systemic inflammation markers in silica-exposed workers. *Occupational and Environmental Medicine* 69(4):256-260.
- Schwartz J (1994). Air pollution and daily mortality: A review and meta-analysis. *Environmental Research* 64(1):36-52.
- Shankar T, Garhnayak M, Garhnayak L, Dhal A, Kar AK (2017). Comparison of hypersensitivity in metal ceramic crowns cemented with zinc phosphate and self-adhesive resin: A prospective study. *The Journal of Contemporary Dental Practice* 18(10):923-926.
- Sivicommar R, Jayabalou R, Subrahmanyam YV, Jothikumar N, Swarnalatha S (2001). Air pollution in stone crushing industry and associated health effect. *Indian Journal of Environmental Health* 4:169-173.
- Thomas P, Summer B, Sander CA, Przybilla B, Thomas M, Naumann T (2000). Intolerance of osteosynthesis material: evidence of dichromate contact allergy with concomitant oligoclonal T-cell infiltrate and Th1-type cytokine expression in the peri-implantar tissue. *Allergy* 55:969-972.
- Zelege ZK, Moen BE, Brátveit M (2010). Cement dust exposure and acute lung function: A cross shift study. *BMC Pulmonary Medicine* 10:19.

*Full Length Research Paper*

# **Phytochemical, acute and subacute toxicity studies of *Annona senegalensis* Pers. (Annonaceae) root wood extracts**

**Sylvain ILBOUDO<sup>1,2\*</sup>, Hortense SOME<sup>3</sup>, Geoffroy G. OUEDRAOGO<sup>1</sup>, Félix B. KINI<sup>1</sup>,  
Sylvin OUEDRAOGO<sup>1</sup> and Innocent P. GUISSOU<sup>1,3</sup>**

<sup>1</sup>Laboratoire de Toxicologie Département Médecine, Pharmacopée Traditionnelles et Pharmacie, Institut de Recherche en Sciences de la Santé (MEPHATRA-PH/IRSS/CNRST), 03 BP 7192 Ouagadougou, Burkina Faso.

<sup>2</sup>Unité Mixte de Recherche Internationale - Environnement, Santé, Sociétés (UMI 3189, ESS) CNRS/CNRST/UCAD/UGB/USTTB, Burkina Faso.

<sup>3</sup>Unité de Formation et de Recherche en Science de la Santé (UFR-SDS), Université Ouaga-I Pr Joseph KI-ZERBO, 03 BP 7021 Ouagadougou, Burkina Faso.

Received 23 February, 2019 ; Accepted 15 April 2019

**Considered safe because being from natural origin, plant products can exhibit toxic effects during their use. To ensure safe use of *Annona senegalensis* Pers. (Annonaceae), plant widely used for its therapeutic potential, the phytochemical and safety profiles of its root wood were investigated. Standard tube characterization tests were used to highlight phytochemical groups of root wood of the plant. Acute and subacute toxicity tests were carried out in Medical Research Institute (NMRI) mice following the Organization for Economic Cooperation and Development (OECD) test guidelines. The phytochemical screening showed the presence of sterols and triterpens, polyphenols, reducing compounds, and flavonoids in root wood of *Annona senegalensis* (*A. senegalensis*). In toxicological studies, the results indicate that the aqueous extract has a low acute toxicity with an LD50 greater than 5000 mg/kg b.w. The results of subacute toxicity study indicate that the mice receiving 300 mg/kg b.w. of extract experienced mildly decreased body weights in comparison with the control in non-significant manner, especially at the fourth week. After 28 days of treatment, apart aspartate aminotransferase (AST), no significant changes were found in the blood serum biochemical parameters such as total proteins, alanine aminotransferase (ALT), glucose, creatinin, and lipid levels of the treated mice in comparison with the control group. In view of the current results, *A. senegalensis* root wood aqueous extract would be considered as safe in both acute and subacute exposure. However, long-term toxicity studies are needed for further toxicological profile elicitation of the plant, and a possible reinforcement of clinical relevance of the results of laboratory studies.**

**Key words:** *Annona senegalensis*, blood chemistry, Medical Research Institute (NMRI) mice, phytochemical compounds, sex-related toxicity, traditional medicine.

## **INTRODUCTION**

A wide range of plant species has been used by man since the dawn of medicine for his health care. Because traditional herbal medicine play significant and increasing

roles in global healthcare in Asia, Africa, Americas, Australasia, and Europa (WHO, 2005), there is a real surge on the practice over the world. At the

International Conference on Traditional Medicine for South-East Asian Countries in February 2013, the WHO Director-General, Margaret Chan, stated that “traditional medicines, of proven quality, safety, and efficacy, contribute to the goal of ensuring that all people have access to care. For many millions of people, herbal medicines, traditional treatments, and traditional practitioners are the main source of health care, and sometimes the only source of care” (WHO, 2013). This assertion is consistent with WHO estimate which indicate that approximately 80% of the populations of developing countries still rely on a traditional system of medicine based on herbal drugs for primary healthcare (OMS, 2002).

In addition to their established pharmacological properties, one of reasons of the resurgence of interest in plant-based treatments is that herbal medicines, being “natural”, are considered as harmless (Ekor, 2014). Despite this positive perception of herbal treatments, their safety has most often not been evaluated per modern standards (Cheng and Leung, 2012; Pelkonen et al., 2014), and cases of contamination, adulteration, toxicity, or poisoning are regularly detected (Vanherweghem et al., 1993; Liu et al., 2014).

Until now, only a few quality toxicological studies have been carried out on the most widely used herbs; it is estimated that toxicological data are still missing for up to 90% of traditional Chinese herbal medicines (Cheng and Leung, 2012), and the situation appears even worse for herbs used in developing countries, notably in African traditional medicine (Kahumba et al., 2015; Poivre et al., 2017).

*Annona senegalensis* from Annonaceae family is one of the multiple medicinal plants widely used for their therapeutic potentials. The results of ethnopharmacological studies support this folk use of the plant. Indeed, Okhale et al. (2016) reported the use of all parts of *A. senegalensis* for the treatment of different ailments including yellow fever, tuberculosis, small pox, snake bites, hernia, necrotizing venoms, erectile dysfunction, difficulty in swallowing, infectious diseases, gastritis, male sexual impotence, diabetes. These popular uses are consistent with the numerous pharmacological properties of the plant (Okhale et al., 2016; Ngbolua et al., 2017) including anticonvulsant (Konaté et al., 2012; Igwe and Nwobodo, 2014), antibacterial (Jada et al., 2014, 2015), anthelmintique (Nguessan et al., 2017), antidrepanocytary (Mpiana et al., 2012), anti-inflammatory (Yeo et al., 2011), antivenous (Adzu et al., 2005; Oladele et al., 2014; Emmanuel et al., 2014), antitripanosomal (Kabiru et al., 2010), and anti-hyperglycemic (Nanti et al., 2018) activities.

Phytochemical screening of several organs of the plant revealed presence of numerous secondary metabolites as alkaloids, glycosides, tannins, flavonoids, carbohydrates and saponins in root (Igwe and Nwobodo, 2014; Ijaiya et al., 2014), sterols and/or triterpenes, anthocyanes, glucids, coumarins, flavonoids and alkaloids in root barks (Konaté et al., 2012), polyphenols, sterols and polyterpenes, flavonoids, quinonic compounds, alkaloids, and catechic tannins in leaves (Ijaiya et al., 2014; Nanti et al., 2018). Furthermore, extracts of several parts of the plant, with the exception of the root woods ones, have undergone toxicological investigations (Konaté et al., 2012; Okoye et al., 2012; Rukayyah and Onyinyechi, 2016; Nanti et al., 2018). Phytochemical and toxicological data on root wood are therefore very scarce. The objectives of the present study was to establish the phytochemical profile of *A. senegalensis* root wood, and to evaluate the acute and subacute oral toxicity of its aqueous extract *in vivo* in experimental animal.

## MATERIALS AND METHODS

### Plant

The roots of *A. senegalensis* were collected in May 2013 in the field of the experimental station of the Research Institute for Development of Gampéla, located at 25 km at East of Ouagadougou, Burkina Faso capital. The geographical coordinates of the harvest site are 12° 25 ' North latitude and 1° 21' West longitude. A sample of harvested plant was identified and authenticated at the “Laboratoire de Biologie et d'Ecologie Végétales de l'Université Ouaga 1 Pr Joseph KI-ZERBO” where the voucher specimen has been deposited under number 6794.

The roots were washed, separated from their bark and the wood was dried in shade under ventilation and then powdered using a mechanical grinder (Gladiator Est. 1931 Type BN 1 Mach. 40461 1083). The powder obtained was used for phytochemical characterization and preparation of extracts for biological investigation. Prior the operations of extraction for phytochemical and biological further investigations, the plant powder was submitted to the relative humidity rate (RHR) determination. Thus, 1 g ( $W_i$ ) of root wood powder has been placed in a oven (110°C) during 1 h in order to get a constant dry weight ( $W_f$ ). The operation is repeated independently five times to allow the calculation of the average RHR according to the formula (Reeb and Milota, 1999):

$$RHR (\%) = \frac{W_i - W_f}{W_i} \times 100$$

Where,  $W_i$  and  $W_f$  are the respective initial final weights of powder.

### Animals

Toxic effects of the aqueous extract of root wood of *A. senegalensis* were assessed *in vivo* in NMRI mice. Mice (average weight of 31 ±

\*Corresponding author. E-mail: sylvain.ilboudo@gmail.com.

5 g), procured from the "Centre International de Recherche-Développement sur l'Élevage en zone Subhumide" (CIRDES), Burkina Faso, were used for the study. All animals were maintained in a controlled temperature room of  $22 \pm 3^\circ\text{C}$  with a 12 h dark/light cycle. Animals had free access to water and standard laboratory pellet enriched with protein (29%). The protocol of experimentation using animals was carried out in accordance with protocols already validated by the Research Institute of Health Sciences (IRSS, Burkina Faso) and that meet international standards as described in OECD Guidance Document No. 19 (Guidance Document on the Recognition, Assessment and Use of Clinical Signs as Humane Endpoints for Experimental Animals Used in Safety Evaluation) (OECD, 2000).

## Plant extracts preparation

### Extraction for phytochemistry

The extracts for phytochemical screening were obtained by successive leaching of dried root wood powder from *A. senegalensis* with solvents of increasing polarity (dichloromethane, aqueous methanol solution (80: 20 v/v) and distilled water). Thus, 10 g of the dry vegetable drug was macerated for 24 h with 100 mL of dichloromethane and then leached with the same solvent until exhaustion. The pomace was then dried in a ventilated oven at  $40^\circ\text{C}$ . On the dry pomace, the same extraction process was carried out with an aqueous methanol solution (80: 20 v/v), then with distilled water. A portion of the hydro-methanolic fraction was hydrolyzed in an acidic medium for the characterization of the total o-glycoside genins. Four fractions of extracts were thus obtained for the screening of the phytochemical groups of the sample.

### Acid hydrolysis of the hydro-methanol extract

A volume of 50 mL of the hydro-methanolic extract was placed in a 250 mL flask. A volume of 25 mL of a 10% hydrochloric acid solution was added to the extract. The acid mixture is boiled under reflux for 30 min. After cooling, 25 mL of distilled water was added to the contents of the flask and the whole was transferred to a 100 mL separatory funnel. The solution was extracted by liquid-liquid partition into a separatory funnel with  $4 \times 15$  mL of dichloromethane. The organic phases were combined and dried over anhydrous sodium sulfate. The dehydrated organic phase was filtered on Whatman paper. The filtrate was then concentrated by half under reduced pressure on a rotavapor-type evaporator (Rotavapor - Büchi 461).

### Extraction for toxicity tests

For toxicity tests purpose, an aqueous extract of dried root wood powder from *A. senegalensis* was prepared in the distilled water. Thus, 100 g of powder sample was mixed with distilled water (1000 mL) in a sterile flask. The mixture was homogenized with a glass rod and left to macerate with mechanical stirring at room temperature for 24 h. After 24 h, the aqueous maceration was filtered and then centrifuged (2000 trs/min, 5 min). The supernatant was collected, concentrated and frozen before lyophilised. The total weight of lyophilized extract was measured for the calculation of the extraction yield (Y) by the following formula:

$$Y (\%) = \frac{W_e}{W_p \times RHR} \times 100$$

Where RHR is relative humidity rate of the plant powder,  $W_p$  and  $W_e$

are the respective initial powder and final lyophilized extract weights.

## Phytochemical screening

Phytochemical tests were performed according to the method of Ciulei (1982) adapted at the Laboratory of Phytochemistry from the Institute of Research in Health Science (IRSS), Ouagadougou (Ouedraogo et al., 2016). Fractions of extracts obtained by successive leaching of plant material were tested for the presence of alkaloids (Mayer, Wagner, and Dragendorf tests), flavonoids (Reaction of Shibata or cyanidine test), anthracenosides (reaction of Bornträger's), carotenoids (reaction of Carr Price's), coumarins (reaction of Feigl), sterols and triterpenes (reaction of Liebermann-Burchard's), tannins (Ferric chloride test), reducing compounds (Fehling liqueur test), leucoanthocyanosides (Bate-Smith test), and saponosides (foam test).

## Acute toxicity test

Acute oral toxicity test refers to those adverse effects occurring following administration of a single dose of a substance, or multiple doses given within 24 h. It was performed on both male and female NMRI mice in accordance with Organization for Economic Cooperation and Development (OECD) test guideline 423 (OECD, 2001). Briefly, after a 3 h fastening period, the extract was administered orally by gavage in single dose to the mice according to the sequential procedure. While conducting the test, 2000 mg/kg body weight (b.w.) of extract was chosen as the starting dose. Animals were observed individually during the 2 h post-treatment to the end of which they were fed. They are then observed at least once daily for 14 days period for mortality and signs of toxicity such as changes in skin and fur, eyes, mucus membranes, convulsion, salivation, diarrhoea, lethargy, sleep and coma. Water consumption was monitored daily for each cage up to two weeks. Body weight and food consumption were recorded the first, second, third, seventh and fourteenth days. On the 14th day, after weighing, all the mice were euthanized using ketamine, then their internal organs removed, examined and weighted. A control group of male and female mice received a single dose of distilled water orally and have been monitored for 14 days as well as the treated group.

## Sub-acute toxicity test

Subacute systemic toxicity is defined as adverse effects occurring after multiple or continuous exposure to a substance between 24 h and 28 days (De Jong et al., 2012). The sub-acute oral toxicity study was carried out according to OECD guideline 407 (OECD, 2008) with slight modification. Male mice were randomly divided into three groups of 5 animals each, each group kept in separate polypropylene cages. Group 1 served as control and received a daily administration of vehicle (distilled water). Groups 2 and 3 received extract doses of 30 and 300 mg/kg body weight, respectively. The extract and vehicle were administered daily at the same time for 28 days. All animal's were closely observed for the first 1 and 4 h of dosing to examine any adverse toxic signs, behavioural changes and at least twice a day for morbidity and mortality. Body weight and food consumption were recorded once weekly. Water consumption was monitored daily for each cage (5 mice per cage) up to 4 weeks. On the 29th day, after over-night fastening, all the mice were anaesthetized using ketamine and blood samples collected via cardiac puncture into dry tube (vacutainers) for each animal.



**Table 1.** Qualitative phytochemical analysis of root wood powder from *A. senegalensis*.

Fraction	Phytochemical groups	Result
Dichloromethane fraction	Alkaloids bases	-
	Flavonic aglycones	-
	Genin of anthracenosides	-
	Carotenoids	-
	Coumarins	-
	Sterols and triterpenes	+
Hydro-methanolic fraction	Polyphenols (tannins)	+
	Reducing compounds	+
	Leucoanthocyanosides	-
	Saponosides	-
Hydrolysate of hydro-methanolic fraction	Flavonic aglycones	+
	Sterols and triterpenes	+
	Coumarins	-
Aqueous residual fraction	Reducing compounds	+
	Polyphenols (tannins)	-
	Saponosides	-

+ = Present; - = Absent

### Blood analysis

The blood samples in dry vacutainers were centrifuged at 3000 rpm for 10 min using a table centrifuge (ROTOFIX 32A, Mettich Zenfrifugen, Germany); the sera obtained were used for biochemical assays. Blood chemistry tests were performed on an automatic biochemistry analyzer (Automate Jenway 6400). Serum alanine aminotransferase (ALT), aspartate aminotransferase (AST), creatinin (CREAT), lipides, total proteins, and glucose were determined.

### Effects on vital organs

After blood collection, internal organs including heart, lungs, liver, kidneys, and spleen were collected carefully from sacrificed animal. The surface of isolated organs were dehydrated with cotton wool and weighed on a analytical balance (Sartorius, model 1702). Each weighed organ was standardized for 100 g body weight of each mouse weighed to determine relative organs weights. After that, a gross examination (macroscopic analysis) of the target organs of the control and treated animals was done to check any significant change in texture and shape.

### Statistical analysis

Results are expressed as means  $\pm$  standard deviation (SD). If applicable, means and standard deviations were calculated separately for males and females. The data were processed with Graph Pad Prism.5. The statistical significance of difference between treated and control groups were analyzed using one-way analysis of variance (ANOVA), followed by Dunett's multiple comparison tests. Differences were considered to be statically significant at  $p < 0.05$ .

## RESULTS

### Phytochemical screening

The relative humidity rate (RHR) was  $3.96 \pm 0.03\%$  and the average yield (Y) was  $6.89 \pm 0.22\%$ . The extract and its lyophilizate gave a bitter taste.

The phytochemical screening on *A. senegalensis* root wood powder (dichloromethane, MeOH/water solution and water) extracts indicated the presence of sterols and triterpenes, polyphenols (tannins), reducing compounds, and flavonic aglycones. The results are presented in Table 1.

### Acute toxicity study of the plant extract

#### Mice mortality record

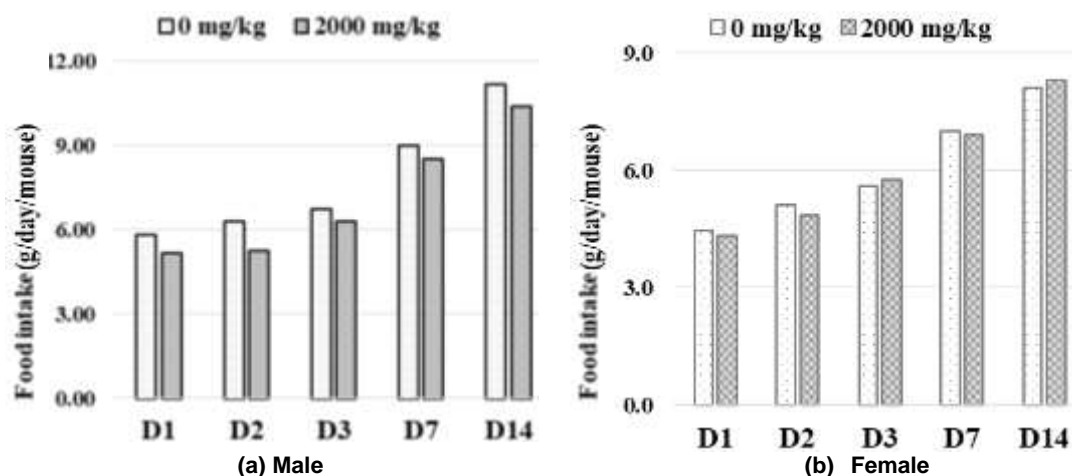
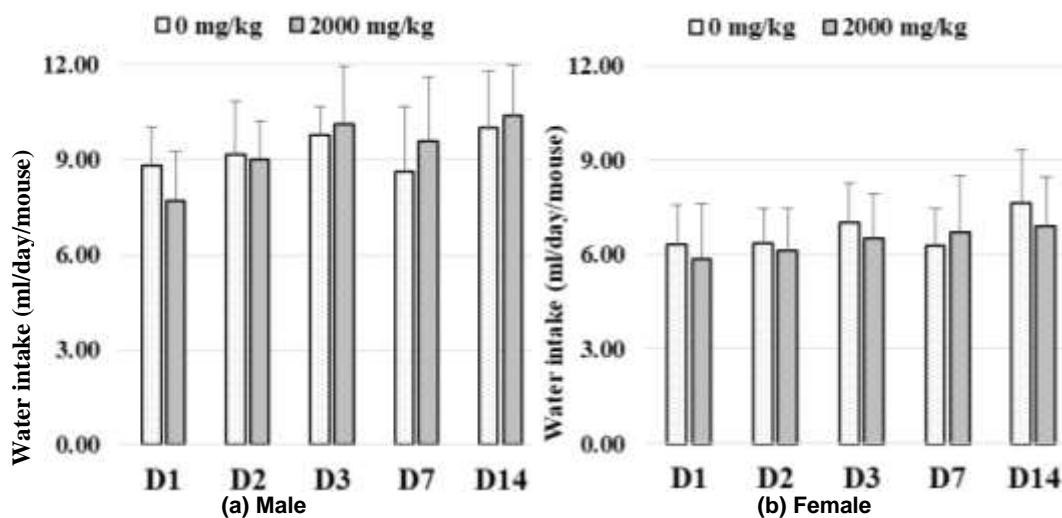
After 2000 mg/kg single dose administration of *A. senegalensis* extract, there was no animal death in the first step of the study. Further more, upon the 14-day observation period, no sign of toxicity was noted in the wellness parameters of the animals. A similar observation was made in the second step study. The results of acute toxicity study are presented in Table 2. According to the OECD acute toxic class method, the oral LD<sub>50</sub> of the tested extract is estimated to 5000 mg/kg b.w.

#### Effect of oral acute administration of extract on mice food and water intake

The food intake of both control and treated mice was

**Table 2.** Mortality of male and female mice in acute oral toxicity study.

Dose (mg/kg b.w.)	No. of death / Initial No. of male mice		No. of death / Initial No. of female mice	
	First step	Second step	First step	Second step
0	0/3	0/3	0/3	0/3
2000	0/3	0/3	0/3	0/3

**Figure 1.** Food intake evolution on control and mice acutely exposed to *A. senegalensis* root wood extract.**Figure 2.** Water intake evolution on control and mice acutely exposed to *A. senegalensis* root wood extract.

increased continuously with respect to their initial food intake (Figure 1). This observation was the same in both male and female mice. In male mice receiving the plant extract, there was a decrease in food consumption compared to controls. This decline of food intake ranged from 0.5 to 1 g. Unlike males, no significant changes in food consumption were observed in treated female mice

compared to controls.

The results of the water consumption are as shown in Figure 2. Compared to the values recorded in the controls, it is noted that the aqueous extract of *A. senegalensis* root wood, at a single dose of 2000 mg/kg b.w. did not affect water intake, either in male mice or in female mice.

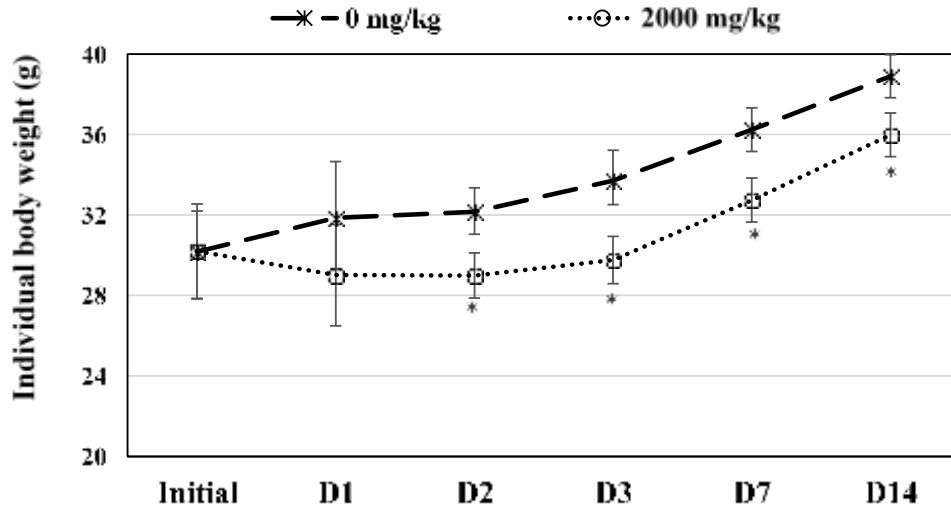


Figure 3. Mean body weight of both control and acute treated male mice.

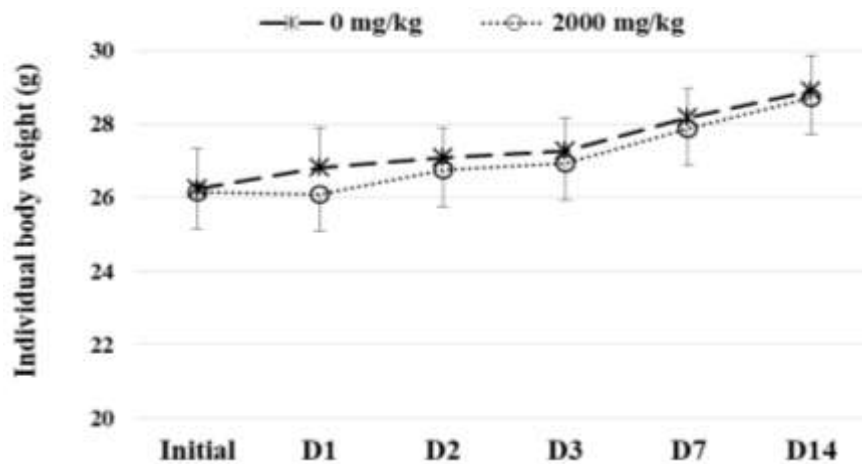


Figure 4. Mean body weight of both control and acute treated female mice.

**Effect of oral acute administration of extract on mice body and organs weights**

**Body weight:** The body weight of all the both male and female mice increased with respect to their initial value. From 2nd to 14th, the male mice received extract at dose of 2000 mg/kg b.w. single exhibited significant ( $p < 0.05$ ) loss in body weight gain comparatively to control group (Figure 3). For female, no significant differences ( $p > 0.05$ ) were observed in the body weight of extract treated mice compared to their respective control measurements (Figure 4).

**Organs relative weight:** At a single oral dose of 2000 mg/kg, the results showed there was no significant difference ( $p > 0.05$ ) in the relative organ weights of the extract treated mice with respect to the mice of control

group (Table 3).

**Sub-acute toxicity**

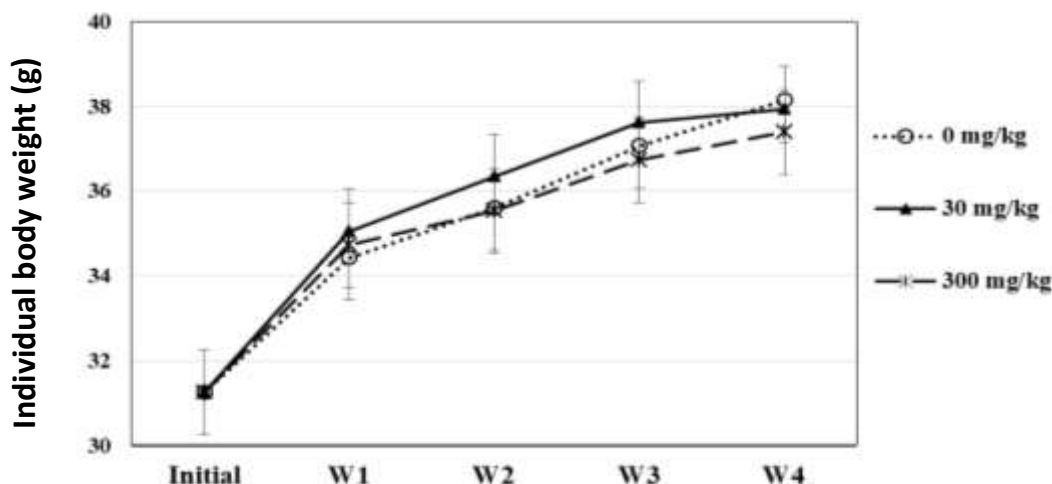
There was no change in normal behavioral pattern of animals treated with extract, and no sign and symptoms of toxicity were observed during the daily observations which were done continuously upon the 28 days of the study.

**Effect of oral subacute administration of extract on mice body and organs weights**

**Body weight:** The results of recorded body weights of the mice treated with root wood aqueous extract of A.

**Table 3.** Mean relative organ weights after an acute treatment with *A. senegalensis* root wood aqueous extract.

Dose (mg/kg b.w.)	Sex	Organs relative weight (mean $\pm$ SD)				
		Heart	Lung	Liver	Kidneys	Spleen
0	M	0.400 $\pm$ 0.033	0.434 $\pm$ 0.048	4.634 $\pm$ 0.307	1.422 $\pm$ 0.175	0.500 $\pm$ 0.142
	F	0.406 $\pm$ 0.055	0.444 $\pm$ 0.058	4.446 $\pm$ 0.335	1.350 $\pm$ 0.136	0.536 $\pm$ 0.143
2000	M	0.386 $\pm$ 0.038	0.432 $\pm$ 0.029	4.578 $\pm$ 0.396	1.436 $\pm$ 0.124	0.511 $\pm$ 0.033
	F	0.410 $\pm$ 0.071	0.428 $\pm$ 0.050	4.514 $\pm$ 0.312	1.366 $\pm$ 0.162	0.486 $\pm$ 0.140

**Figure 5.** Mean body weight of both control and treated mice with *A. senegalensis* root wood aqueous extract.**Table 4.** Mean relative organ weights of mice after 28 days treatment with *A. senegalensis* root wood aqueous extract.

Dose (mg/kg b.w.)	Relative organ weights (mean $\pm$ SD)				
	Heart	Lung	Liver	Kidneys	Spleen
0	0.402 $\pm$ 0.037	0.474 $\pm$ 0.200	4.234 $\pm$ 0.340	1.402 $\pm$ 0.054	0.536 $\pm$ 0.159
30	0.396 $\pm$ 0.023	0.476 $\pm$ 0.170	4.150 $\pm$ 0.460	1.350 $\pm$ 0.025	0.526 $\pm$ 0.091
300	0.398 $\pm$ 0.043	0.458 $\pm$ 0.140	4.176 $\pm$ 0.440	1.346 $\pm$ 0.033	0.535 $\pm$ 0.037

*senegalensis* (doses of 30 and 300 mg/kg b.w.) are presented in Figure 5. For control as well as treated mice, the results show a steady increase in the body weight (from  $\approx$  31 to  $\approx$  38 g) upon the 28 days of study. According to Figure 5, mice treated with extract at the daily dose of 30 mg/kg for 28 days showed increased body weight gain in comparison with the control in a non-significant fashion, the second and third weeks. The mice receiving 300 mg/kg showed non-significant decrease of body weight gain in comparison with the control, especially at the fourth week.

**Macroscopic effects of *A. senegalensis* extract on vital organs:** Macroscopic examination of vital organs such as heart, lung, liver, kidney, and spleen of control and treated animals with root wood aqueous extract show

that extract does not affect vital organs as there was no change in color and aspect of different organs.

**Relative organ weights:** After 28 days daily dosing of mice with *A. senegalensis* extract or distilled water and animal organs were prelevated and weighted. Table 4 shows the results. No significant differences were observed in the weights of all organs compared to their respective control measurements.

**Effect of oral administration of *A. senegalensis* root wood aqueous extract on water and food consumption**

**Food intake:** During the 28 days of study, the food intake

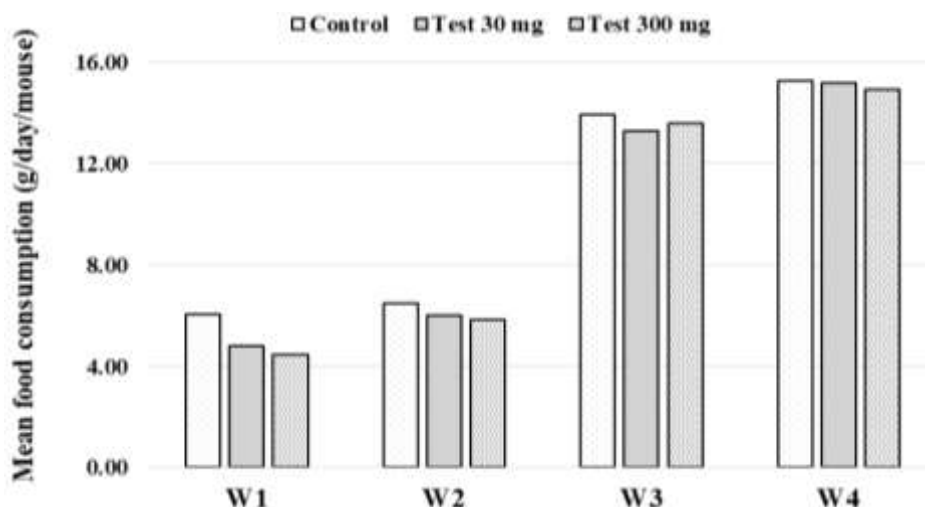


Figure 6. Food intake in subacute toxicity study.

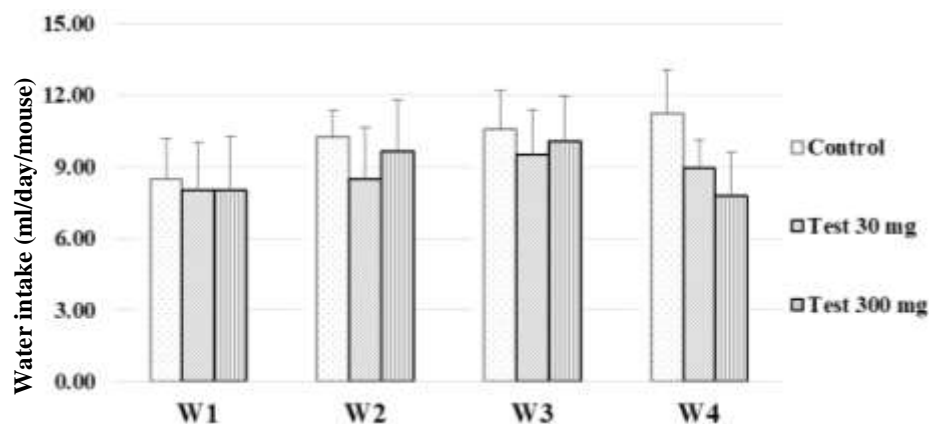


Figure 7. Food intake in subacute toxicity study.

of both control and treated mice was increased continuously with respect to their initial food intake (Figure 6). During the first week, a clear decrease in food consumption was noted in mice receiving the plant extract compared to controls. This decline of food intake ranged from 1.24 to 1.54 g at 30 and 300 mg/kg/day, respectively.

**Water consumption:** The results of daily water intake measure during the 28 days of the study period are presented in Figure 7. The average water consumption of treated groups showed a decrease, especially during the fourth week, in comparison with the control but in a non-significant manner.

**Effect of extract on biochemical parameters of mice**

Table 5 shows the results of biochemical parameters of

treated animals and control ones. Except for AST, *A. senegalensis* root wood aqueous extract did not cause significant changes in blood serum biochemical parameters such as total proteins, alanine aminotransferase, glucose, creatinin, and lipid levels when compared with control group. Both dose of extract (30 and 300 mg/kg b.w.) induced significant changes ( $p < 0.05$ ) in AST value of treated mice comparatively to control animals.

**DISCUSSION**

*A. senegalensis* is a plant widely used in several countries of South-Saharan Africa and even outside the continent, in human or veterinary medicine. Numerous ethnomedicinal uses have been attributed to different parts of the plant, as well as its use as food and food additives (Okhale et al., 2016). *A. senegalensis* root

**Table 5.** Biochemical parameters for mice after 28 days treatment with *Lannea microcarpa* trunks barks aqueous extract.

Dose (mg/kg b.w.)	Biochemical parameter					
	ALT (U/L)	AST (U/L)	CREAT (mmol/L)	Glucose (mmol/L)	Proteins (g/dl)	Lipids (mg/dl)
0	38.03 ± 5.91	4.86 ± 0.67	0.94 ± 0.16	7.49 ± 2.52	4.55 ± 0.18	539.90 ± 66.79
30	39.28 ± 4.30	8.42 ± 1.81**	1.25 ± 0.17	8.87 ± 2.94	6.04 ± 0.28	370.09 ± 56.59
300	43.25 ± 6.42	9.68 ± 1.41**	1.15 ± 0.10	9.16 ± 2.80	5.22 ± 1.08	425.52 ± 75.65

wood is used as a toothpick in Burkina Faso (Nacoulma, 1996) and Central African Republic (Ake et al., 1978) for smoking cessation. Generally, the resurgence of interest in plant-based treatments seems to have various origins: it may come from patients disappointment with standard treatments (in terms of efficacy and/or safety), from the rewarding feeling of active participation in the choice of therapeutic means, from the beliefs that the use of herbs is associated with a healthier lifestyle, and that herbal medicines, being “natural”, are therefore harmless (Ekor, 2014). However, although often perceived as innocuous by the general public, herbal substances harbor phytochemicals responsible of toxic effects (Babu et al., 2016; Poivre et al., 2017; Hudson et al., 2018). However, both phytochemical and toxicological investigations on root wood are very scarce. For safe use of *A. senegalensis* root wood, it was necessary to establish its toxicological and phytochemical profiles.

In the present study, the relative humidity rate (RHR) of the powder from the root wood of the plant were determined. This parameter, which measures the water content of the drug, was less than 10%. This indicates that the powder of the plant can be stored for a long time in good conditions without major risk of deterioration of chemical principles (Paris and Moyse, 1965; WHO, 1998). The extraction yield measuring the solvent efficiency to extract specific components from the original material (Fayera et al., 2018) was  $6.89 \pm 0.22\%$ . Igwe and Nwobodo (2014) obtained a yield of 30% by extracting *A. senegalensis* root with water. The yield obtained is slightly upper relative to that reported by Adzu et al. (2005) with *A. senegalensis* root bark extracted with methanol (5.58%).

Chemical constituents determine the biological activities of the plant, whether the activity is a toxicity or a pharmacological property. Many plants produce toxic secondary metabolites as natural defence from adverse conditions. In some toxicologically and medicinally relevant plant species, these toxic substances are not distinguished from therapeutically active ingredients (Ifeoma and Oluwakanyinsola, 2013). In the present study, qualitative phytochemical analysis made for the root wood of *A. senegalensis* revealed the presence of sterols and triterpenes, polyphenols (tannins), reducing compounds, and flavonic aglycones. Konaté et al. (2012) had shown the presence of sterols and/or triterpenes, anthocyanes, glucids, coumarins, flavonoids and alkaloids

in root bark of *A. senegalensis* from Burkina Faso. Comparing the present results with those of Konaté et al. (2012), one can speculate that root bark is qualitatively richer in chemical groups than root wood. Indeed, in addition to the chemical groups present in the wood, the barks also contain anthocyanins, coumarins, and alkaloids. However, the wood contains tannins that are not highlighted in bark. Either one or combination of detected chemicals may be responsible of biological activities of root wood.

In view of the strong traditional use of the root, this study investigates the safety of this part of the plant by determination of eventual detrimental effects. For the toxicological investigation, the oral administration of a single dose of aqueous extract in both male and female mice at 2000 mg/kg b.w. is performed. No effect on mortality, examined clinical sign, water consumption and relative organic weight are observed. Absence of mortality permits to estimate the median lethal dose ( $DL_{50}$ ) at 5000 mg/kg b.w. in accordance with the Guideline 423 of OECD (2001). With such median lethal dose, aqueous extract of *A. senegalensis* is classified to belong to substance unlikely to present acute hazard according to the Globally Harmonized System of Classification and Labeling of Chemicals of the United Nations (ONU, 2017). These results is in agreement with those of previous studies which has noted the absence of mortality by intraperitoneal single dose of 3000 mg/kg b.w. (Konaté et al., 2012) and oral single dose of 5000 mg/kg b.w. (Nanti et al., 2018) with root bark of the plant. In male mice, a mild decrease in food consumption was noted comparatively to control male mice. Interestingly, the decrease in food intake is correlated with a reduction in weight gain upon exposure to aqueous extract of root wood of *A. senegalensis*. Such results was not observed by Nanti et al. (2018) in rat. These authors showed that single oral doses of aqueous extract of *A. senegalensis* root barks (550, 1,750, and 3,000 mg/kg b.w.) administered to the rats, did not induce significant variation of weight in these animals after two weeks of monitoring.

The body weight decrease in this study may be the consequence of plant extract compounds actions on the digestive system of the test animals. Indeed, tannins, water-soluble polyphenols highlighted in *A. senegalensis* root wood by this study, have been reported to be responsible for decreases in feed intake, growth rate,

feed efficiency, net metabolizable energy, and protein digestibility in experimental animals (Chung et al., 1998). They are the ability to form indigestible complexes with the nutrients of foods such as iron and food proteins (Butler, 1992), or with the proteins of the organism such as digestive enzymes (Kumar and Singh, 1984). This results in an inhibition of the absorption of complexed nutrients and the decrease in the activity of digestive enzymes with consequent reduction of nutritional efficiency. The action of these compounds can be maintained for up to 15 days after ingestion of the product containing them (FAO, 1992). Note that this action of the extract is practically absent in female mice, since the weight loss is not significant with animals of this sex. Such a dimorphic biological reaction to a chemical is a common phenomenon reported by previous work (Nicolson et al., 2010).

In the sub-acute toxicity study, the daily oral administration of root wood aqueous extract from *A. senegalensis* at doses of 30 and 300 mg/kg /day b.w. during four weeks did not cause any death or clinical signs of toxicity in mice. During the study period, a steady increase in the body weight was observed in both treated and control animal groups. Measures of animal growth are routinely evaluated in toxicology studies and are key to interpretation of compound-related effects (Hoffman et al., 2002). After 28 days of treatment, the mice which received extract at dose of 300 mg/kg/day b.w. experienced mildly decreased body weights in comparison with the control in non-significant manner, especially at the fourth week. This drop in weight is not sufficient to conclude to a toxicity of the extract. Interestingly, the food intake and water consumption were similar in the treated groups comparatively to the control one.

Macroscopic examination of vital organs such as heart, lung, liver, kidney, and spleen of control and treated animals show that the extract does not induce change in color and aspect of different organs. In addition, no significant differences were found in the organ weights of the treated animals in comparison with the control groups. As organ weight evaluation is an essential part of the toxicologic and risk assessment of chemicals from miscellaneous sources (Michael et al., 2007), the results suggest a possible absence of extract-related organs toxicity.

In addition to organs macroscopic examinations and the determination of their relative weight, blood biochemical parameters are commonly used as indicators of organ damages in toxicity study. The results of subacute toxicity study indicate that, with the exception of the AST value, no significant changes were found in the blood serum biochemical parameters such as total proteins, alanine aminotransferase, glucose, creatinin, and lipid levels of the treated mice in comparison with the control groups. Rukayyah and Onyinyechi (2016) showed that a subacute intraperitoneal administration of

dried carpels methanol/water (1:1) extract of *A. senegalensis* did not induce significant increase in the serum level of ALP and ALT in mice, a concentration dependent decrease of AST. Alanine amino transaminase (ALT) and Aspartate amino transaminase (AST) are largely used for the assessment of liver damage by drugs or any other hepatotoxin (Ramaiah et al., 2011). Although both Aspartate and Alanine aminotransferases are highly concentrated in the liver, AST is also diffusely represented in the heart, skeletal muscle, kidneys, brain and red blood cells, while ALT has low concentrations in skeletal muscle and kidney. An increase in ALT serum levels is, therefore more specific for liver damage (Giannini et al., 2005). Furthermore, the liver is well designed for its central role in carbohydrate, protein and fat metabolism. While ALT and AST are used for specific damaging reaction of liver to toxic, blood proteins, glucose, and lipids level can serve to assess global hepatic functional status. No change was noted in blood glucose concentration. These results are similar to those of Nanti et al. (2018) who noted that *A. senegalensis* root bark extract, at the oral single doses of 50, 200, and 300 mg/kg b.w., does not significantly alter blood glucose values 180 min after the treatment. However, it should be noted that the study design was different, the present study repeated administration in mice while that of Nanti et al. (2018) was single-dose in rats. In the present study, with the absence of significant changes in blood level of both ALT, proteins, glucose, and lipids, one can speculate that aqueous extract of root wood of *A. senegalensis*, at up to daily dose of 300 mg/kg/day b.w. for 28 days, is safe to the liver in mice. However, these results must be supplemented by anatomopathological analyses and long-term toxicity studies (subchronic and chronic) before reaching unequivocal conclusions.

Serum creatinine, an endogenous cation produced mainly by muscle metabolism, is the most widely used marker to assess renal injury (Tschuppert et al., 2007). In the present study, no significant change in creatinine values was found when comparing treated and control groups. This would suggest a safety of aqueous extract of root wood of *A. senegalensis* for mice kidneys at the tested doses, even if these results deserve to be confirmed by anatomopathological examinations.

## Conclusion

In the present study, phytochemical profile and toxicological effect of *A. senegalensis* were investigated. In the present study, phytochemical profile and toxicological effect of root wood from *A. senegalensis* were investigated. Phytochemical screening revealed several chemical groups in the root wood of *A. senegalensis*. The results show that the aqueous extract did not induce mortality in both male and female mice up

to the dose of 2000 mg/kg b.w. However, a sex-related dimorphic profile in the adverse reactions of the extract has been noted. Indeed, male mice showed a significant decrease in body weight correlated with loss of food intake. This weight loss could be attributable to the toxic action of certain compounds of the extract such as tannins. The subacute toxicity test showed that the aqueous extract of wood from the root of the plant exhibit no significant toxic effect up to a dose of 300 mg/kg/day b.w. In view of the current results, subject to results of hematological and anatomopathological analysis, the root wood aqueous extract of *A. senegalensis* would be safe in both acute and subacute exposure conditions. For further clinical relevance of the results, toxicity study must be extended to long term toxicity test as subchronic (90 days repeated administration) and chronic (at least 6 months repeated administration in rodent) toxicity study.

## CONFLICT OF INTERESTS

The authors have not declared any conflict of interests.

## REFERENCES

- Adzu B, Abubakar MS, Izebe KS, Akumka DD, Gamaniel KS (2005). Effect of *Annona senegalensis* root bark extracts on *Naja nigricollis* venom in rats. *Journal of Ethnopharmacology* 96(3):507-513.
- Ake AL, Abeye J, Guinko S, Riguet R, Bangovou Y (1978). Contribution à l'identification et au recensement des plantes utilisées dans la médecine traditionnelle et la pharmacopée en République Centrafricaine. Editions ACCT 1978, 139p.
- Babu SP, Chandrika DG, Kulkarni MR (2016). Plant poisoning—an observational study in a tristate region emergency department. *International Journal of Medical Science and Public Health* 5:2158-2161.
- Butler LG (1992). Antinutritional effects of condensed and hydrolyzable tannins. *Plant Polyphenols* 693–698.
- Cheng KF, Leung PC (2012). Safety in Chinese medicine research. *Open Journal of Safety Science and Technology* 2:32-39.
- Chung KT, Wong TY, Wei CI, Huang YW, Lin Y (1998). Tannins and Human Health: A Review. *Critical Reviews in Food Science and Nutrition* 38(6):421-464.
- Ciulei I (1982). Practical manuals on the industrial utilization of chemical and aromatic plants. Methodology for analysis of vegetable drugs 1st Edn, Ministry of Chemical Industry, Bucharest. P. 67
- De Jong WH, Carraway JW, Geertsma RE (2012). *In vivo* and *in vitro* testing for the biological safety evaluation of biomaterials and medical devices. *Biocompatibility and Performance of Medical Devices*, pp. 120-158.
- Ekor M (2014). The growing use of herbal medicines: issues relating to adverse reactions and challenges in monitoring safety. *Frontiers in Pharmacology* 4(177):1-10.
- Emmanuel A, Ebinbin A, Amlabu W (2014). Detoxification of *Echis ocellatus* venom-induced toxicity by *Annona senegalensis* Pers. *Journal of Complementary and Integrative Medicine* 11(2):93-97.
- FAO (1992). Legume trees and other fodder trees as protein sources for livestock. Par Andrew Speedy and Pierre-Luc Pugliese. FAO Animal Production and Health Paper 102, Rome. <http://www.fao.org/3/T0632E00.htm#TOC>
- Fayera S, Babu NG, Dekebo A, Bogale Y (2018). Phytochemical investigation and antimicrobial study of leaf extract of *Plantago lanceolat*. *Natural Products Chemistry and Research* 6(2):1-8.
- Giannini EG, Testa R, Savarino V (2005). Liver enzyme alteration: a guide for clinicians. *Canadian Medical Association Journal* 172(3):367-379.
- Hoffman WP, Ness DK, Lier RB (2002). Analysis of rodent growth data in toxicology studies. *Toxicological Sciences* 66(2):313-319.
- Hudson A, Lopez E, Almalki AJ, Roe AL, Calderón AI (2018). A review of the toxicity of compounds found in herbal dietary supplements. *Planta Medica* 84:613- 626.
- Ifeoma OE, Oluwakanyinsola O (2013). Screening of Herbal Medicines for Potential Toxicities. *New Insights into Toxicity and Drug Testing* 10.5772/54493. <http://dx.doi.org/10.5772/54493>
- Igwe SA, Nwobodo NN (2014). Anticonvulsant activity of aqueous root extract of *Annona Senegalensis* Pers. *International Journal of Advanced Biological and Biomedical Research* 2(8):2441-2447.
- Ijaiya IS, Arzika S, Abdulkadir M (2014). Extraction and phytochemical screening of the root and leave of *Annona senegalesis* (wild custard apple). *Academic Journal of Interdisciplinary Studies* 3(7):9-15.
- Jada M, Usman W, Adamu Y (2014). In vitro Antimicrobial Effect of Crude Tannins Isolated from the Leaf of *Annona senegalensis*. *International Journal of Biochemistry Research and Review* 4(6):615–623.
- Jada M, Usman W, Olabisi A (2015). Crude Flavonoids Isolated from the Stem Bark of *Annona senegalensis* have Antimicrobial Activity. *Journal of Advances in Biology and Biotechnology* 2(1):24–29.
- Kabiru A, Salako A, Ogbadoyi E (2010). Therapeutic effects of *Annona senegalensis* Pers Stem bark extracts in experimental African trypanosomiasis. *International Journal of Health Research* 3(1):45-49.
- Kahumba JRT, Okusa PN, Bakari A, Bizumukama L, Kalonji J-B, Kiendrebeogo M, Rabemenantsoa C, El Jaziri M, Williamson EM, Duez P (2015). Traditional African medicine: from ancestral knowledge to a modern integrated future? *Science* 350(6262): 61-63.
- Konaté A, Sawadogo WR, Dubruc F, Caillard O, Ouedraogo M, Guissou IP (2012). Phytochemical and Anticonvulsant Properties of *Annona senegalensis* Pers. (Annonaceae), Plant Used in Burkina Folk Medicine to Treat Epilepsy and Convulsions. *British Journal of Pharmacology and Toxicology* 3(5):245-250.
- Kumar R, Sing M (1984). Tannins: their adverse role in ruminant nutrition. *Journal of Agriculture and Food Chemistry* 32:447-453.
- Liu X, Wang Q, Song G, Zhang G, Ye Z, Williamson EM (2014). The classification and application of toxic Chinese Materia Medica. *Phytotherapy Research* 28(3):334-347.
- Michael B, Yano BL, Sellers RS, Perry R, Morton D, Roome N, Johnson JK, Schafer K (2007). Evaluation of organ weights for rodent and non-rodent toxicity studies: A review of regulatory guidelines and a survey of current practices. *Toxicologic Pathology* 35(5):742-750.
- Mpiana PT, Dianzenza EN, Ngbolua KN, Tshibangu DST, Mbala BM, Shetonde OM, Atibu EK, Kakule MK, Bokota MT (2012). Antisickling properties, thermal and photochemical degradations of anthocyanins extract from *Annona senegalensis* (Annonaceae). *International Journal of Biological and Chemical Sciences* 6(5):2241-2251.
- Nacoulma OG (1996). Plantes médicinales et pratiques traditionnelles au Burkina Faso : cas du Plateau Central : Thèse d'Etat ès Sciences Naturelles, Université de Ouagadougou, UFR/SVT, tomes II, 1996, 605p.
- Nanti GGCG, Nene Bi SA, Zahoui OS, Traore F (2018). Comparative study of *Annona senegalensis* (Annonaceae) and *Hallea ledermannii* (Rubiaceae) effects on glycemia in rats. *Journal of Intercultural Ethnopharmacology* 7(1):1-7.
- Ngbolua KN, Moke EL, Baya JL, Djoza R, Ashande CM, Mpiana PT (2017). A mini-review on the pharmacognosy and phytochemistry of a tropical medicinal plant: *Annona senegalensis* Pers. (Annonaceae). *Tropical Plant Research* 4(1):168-175.
- Nguessan CB, Koutouan FP, Eboua NW, Yapo MY, N'din NS, Iritié BM (2017). Évaluation *in vivo* des propriétés anthelminthiques des extraits aqueux d'*Annona senegalensis*. Pers. (Annonaceae) chez les ovins Djallonkés. *Journal of Animal and Plant Sciences* 32(2):5111-5119.
- Nicolson TJ, Mellor HR, Roberts RRA (2010). Gender differences in drug toxicity. *Trends in Pharmacological Sciences* 31(3):108-114.
- OECD (2000). Guidance Document on the Recognition, Assessment and Use of Clinical Signs as Humane Endpoints for Experimental



- Animals Used in Safety Evaluation. Publications Hygiène et Sécurité de l'environnement, Série sur les essais et évaluations No. 19, EN/JM/MONO (2000)7, OCDE, Paris. [https://ntp.niehs.nih.gov/iccvm/suppdocs/feddocs/oced/oced\\_gd19.pdf](https://ntp.niehs.nih.gov/iccvm/suppdocs/feddocs/oced/oced_gd19.pdf)
- OECD (2001). Test No. 423: Acute Oral toxicity - Acute Toxic Class Method, OECD Guidelines for the Testing of Chemicals, Section 4, Éditions OCDE, Paris, <https://doi.org/10.1787/9789264071001-en>.
- OECD (2008). Test No. 407: Repeated Dose 28-day Oral Toxicity Study in Rodents, OECD Guidelines for the Testing of Chemicals, Section 4, Éditions OCDE, Paris, <https://doi.org/10.1787/9789264070684-en>.
- Okhale SE, Akpan E, Fatokun OT, Esievo KY, Kunle OF (2016). *Annona senegalensis* Persoon (Annonaceae): A review of its ethnomedicinal uses, biological activities and phytochemicals. *Journal of Pharmacognosy and Phytochemistry* 5(2):211-219.
- Okoye TC, Akah PA, Ezike AC, Okoye MO, Onyeto CA, Ndukwu F, Ohaegbulam E, Ikele L (2012). Evaluation of the acute and sub acute toxicity of *Annona senegalensis* root bark extracts. *Asian Pacific Journal of Tropical Medicine* 5(4):277-282.
- Oladele G, Faramade I, Ogunbodede M (2014). Effect of aqueous extract of *annona senegalensis* leaves on the spermiogram of male albino rats. *World Journal of Pharmaceutical Sciences* 3(8):409-418.
- OMS (2002). Médecine traditionnelle: Rapport du secrétariat. Conseil exécutif. Cent onzième session. Point 5.7 de l'ordre du jour provisoire. EB111/9 du 12 décembre 2002.
- ONU (2017). Globally Harmonized System of Classification and Labelling of Chemicals (GHS): Seventh revised edition, ONU, New York, 533pp. <https://doi.org/10.18356/e9e7b6dc-en>.
- Ouedraogo GG, Ilboudo S, Ouedraogo N, Ouedraogo S, Diallo D, Guissou IP (2016). Phytochemical study and cardiovascular toxic effects investigation of root barks powder and extracts from *Calotropis procera* (AIT.) R.BR. 5. *World Journal of Pharmaceutical Research* 5(9):299-316.
- Paris R, Moysé H (1965). Matière médicale. Tome I. Masson et Cie éd., Paris, 1965.
- Pelkonen O, Xu Q, Fan TP (2014). Why is research on herbal medicinal products important and how can we improve its quality? *Journal of Traditional and Complementary Medicine* 4(1):1-7.
- Poivre M, Nachtergaeel A, Bunel V, Philippe ON, Duez P (2017). Genotoxicity and Carcinogenicity of Herbal Products. In: Pelkonen O, Duez P, Vuorela P, Vuorela H (Eds.), *Toxicology of Herbal Products*. Springer, Cham, [https://doi.org/10.1007/978-3-319-43806-1\\_9](https://doi.org/10.1007/978-3-319-43806-1_9)
- Ramaiah SK (2011). Preclinical safety assessment: current gaps, challenges and approaches in identifying translatable biomarkers of drug-induced liver. *Clinics in Laboratory Medicine* 31:161-72.
- Reeb J, Milota M (1999). Moisture content by the oven-dry method for industrial testing. *WDKA* 66 – 74. <https://ir.library.oregonstate.edu/downloads/jm214q048>.
- Rukayyah SS and Onyinyechi MG (2016). Determination of acute toxicity and effects of dried carpel of *Annona senegalensis* extract on alkaline phosphatase, amino transferases and body weight in mice. *International Journal of Nutrition and Metabolism Research* 1(1):1-11.
- Tschuppert Y, Buclin T, Rothuizen LE, Decosterd LA, Galleyrand J, Gaud C, and Biollaz J (2007). Effect of dronedarone on renal function in healthy subjects. *British Journal of Clinical Pharmacology* 64:785–791.
- Vanherweghem JL, Tielemans C, Abramowicz D, Depierreux M, Vanhaelen-Fastre R, Vanhaelen M (1993). Rapidly progressive interstitial renal fibrosis in young women: association with slimming regimen including Chinese herbs. *Lancet* 341(8842): 387–391.
- WHO (1998). Quality control methods for medicinal plant materials. World Health Organization Geneva. <http://whqlibdoc.who.int/publications/1998/9241545100.pdf>.
- WHO (2005). National Policy on Traditional Medicine and Regulation of Herbal Medicines. Report of a WHO global survey. <http://whqlibdoc.who.int/publications/2005/9241593237.pdf>
- WHO (2013). WHO Traditional Medicine Strategy 2014 – 2023. NLM classification: WB 55; Hong Kong SAR, China; 78 p. DOI 10.1007/978-3-319-43806-1\_9
- Yeo D, Dinica R, Yapi HF, Furdul B, Praisler M, Djaman AJ, N'Guessan JD (2011). Evaluation of the antiinflammatory activity and phytochemical screening of *Annona senegalensis* leaves. *Thérapie* 66(1):73–80.

Related Journals:

